

Complex Tracheal Repair after Severe Tracheal Rupture during Percutaneous Dilatational Tracheostomy

Luís Filipe Azenha Figueiredo, Ralph A Schmid and Gregor J Kocher*

Division of General Thoracic Surgery, Inselspital, Bern University Hospital, University of Bern, Switzerland

Rec: October 10, 2017; **Acc:** December 05, 2017; **Pub:** December 12, 2017

***Corresponding author:** Gregor J Kocher, Division of General Thoracic Surgery, University Hospital Bern, CH-3010 Bern, Switzerland, Tel: +41-31-6322330; Fax: +41-31-6322327; E-mail: gregor.kocher@insel.ch

Abstract

Percutaneous dilatational tracheostomy (PDT) is a frequently performed procedure in long-term intubated patients. Tracheal laceration is a rarely reported but life-threatening complication which often requires emergent surgical repair in order to re-establish continuity of the airway. This can be a tricky task in polymorbid patients and demands a multidisciplinary approach by intensive care physicians, anesthesiologists, pulmonologists and a surgical team experienced in airway surgery. We herein describe a case of severe iatrogenic tracheal injury occurring during PDT and its management.

Keywords: Tracheal laceration; Percutaneous dilatational tracheostomy; Cervicotomy

Introduction

Since first described in 1985 by P. Ciaglia, percutaneous dilatational tracheostomy (PDT) has become a routine bedside procedure, widely accepted in intensive care units (ICU). Although complications are rare and mostly of minor character (e.g., slight bleeding), serious complications such as tracheal laceration can occur and need prompt multidisciplinary management as demonstrated by the following example.

Case Report

A 37-year-old male was transferred from a peripheral hospital to our ICU for neurological surveillance after left sided hemorrhagic stroke caused by hypertensive crisis. Severe dysphagia and a considerable risk of aspiration required a PDT using the Blue Rhino® Percutaneous Tracheostomy Introducer Kit (Cook Critical Care, Bloomington, IL). Immediately after the procedure the patient showed signs of respiratory distress and developed subcutaneous emphysema of the neck and chest. Placement of bilateral chest tubes for evacuation of bilateral pneumothoraces was performed and the patient was orally re-intubated with distal placement of the tube's tip close to the carina.

An emergency computed tomography showed air around the proximal trachea. Bronchoscopy revealed a complete horizontal tracheal disruption of the cartilaginous part at the location of the tracheostomy (between first and second tracheal ring) and a posterior laceration in form of a separation of the membranous from the cartilaginous part of the trachea on the right side over a length of 4 cm (Figure 1).

Under general anesthesia a horizontal cervicotomy was performed. After blunt dissection of the subcutaneous tissue

and double ligation of the thyroid isthmus the latter was divided and the tracheal injury was visualized. The anterior tracheal wall was debrided and readapted with interrupted polydioxanone sutures (PDS) 3-0. The trachea was then further mobilized and a tension-free adaption of the membranous to the cartilaginous part of the trachea was performed, using interrupted 4-0 PDS sutures.

After the tracheal repair was completed a classic tracheostomy was performed below the third tracheal ring with introduction of a long 10 mm Shiley cannula (Covidien, Boulder, CO) after retraction of the oral intubation tube. The length of the cannula allowed cuff placement distal to the tracheal suture. The thyroid lobes were readapted over the tracheal suture line followed by wound closure layer by layer.

Six days later, after bronchoscopy confirmed good healing of the tracheal mucosa, the patient was discharged to a neurological rehabilitation facility. Three months later the patient is still in rehabilitation with a cuffable fenestrated cannula in place for prevention of recurrent aspirations. Verbal communication was possible but limited by neurological sequelae.

Discussion

According to a review of current PDT techniques the Ciaglia Blue Rhino single dilator kit is the approach with the most favorable safety profile [1].

Citation: Figueiredo LFA, Schmid RA, Kocher GJ. Complex Tracheal Repair after Severe Tracheal Rupture during Percutaneous Dilatational Tracheostomy. Case Rep J. 2017;1(1):001

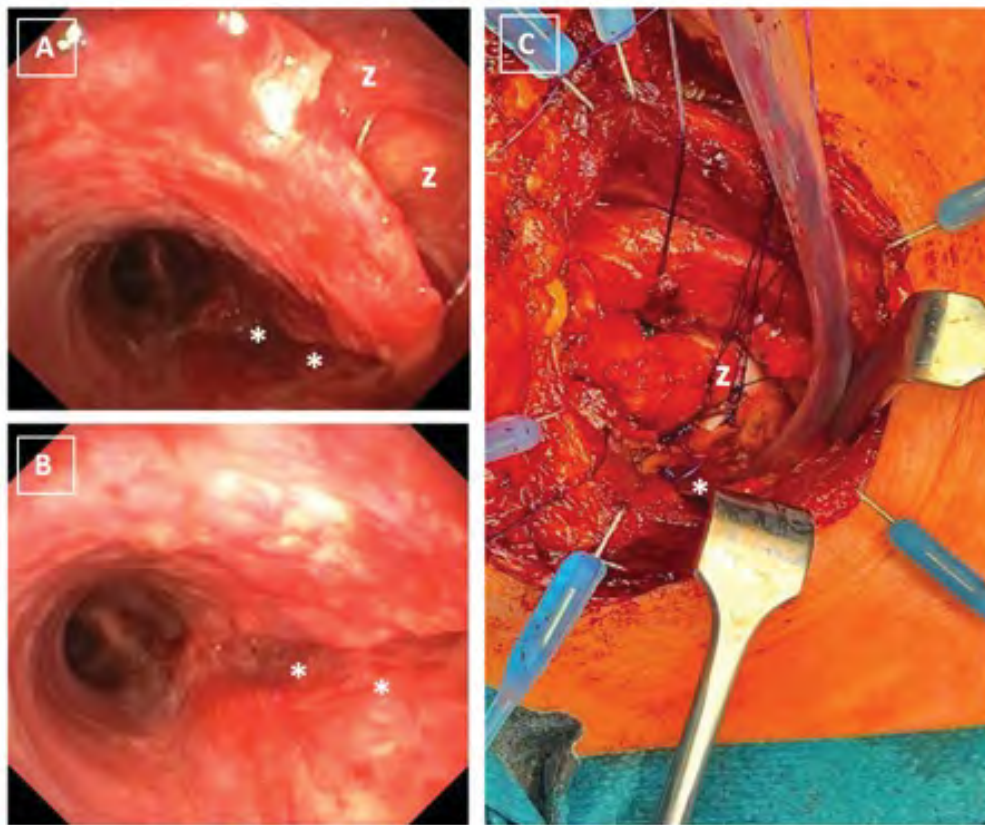


Figure 1: A&B: endoscopic view of the anterior tracheal disruption (z) and the posterior laceration extending towards the carina (*); C: intraoperative view of the surgical field with the head facing to the left. The PDS stitches are placed along the anterior part of the trachea (z) and along the lateroposterior wall on the right (*).

On one hand PDT has been shown to reduce the risk of wound infection and postoperative bleeding when compared to surgical tracheotomy (ST) [2], but on the other hand the PDT technique sometimes lacks optimal visualization of the tracheostomy site which seems to be responsible for the more frequent paratracheal insertions of the cannula in 0.6% to 4% of PDT cases [3]. The reported incidence of posterior tracheal wall and tracheal ring fractures are 1.6% and 9.7%, respectively [3] but its impact on tracheal stenosis are unknown.

Conversion rates from PDT to ST reach from 3% to 7.7% [2,3] and are mostly due to technical difficulties such as the inability to properly insert the cannula or due to significant intraoperative bleeding. Tracheal laceration requiring surgical repair seems to be a rarity, occurring in only 0.2% of cases [4]. However, in case of such an incident, as described in our case report, as first measure the orotracheal intubation tube should be advanced under visual control distal to the rupture site in order to secure the airway. Sometimes even positioning of the intubation tubes' tip in either the left or the right main stem bronchus is necessary in order to completely overlap the laceration.

Conclusion

Progressive subcutaneous emphysema and respiratory distress following PDT should raise immediate suspicion of tracheal laceration. Prompt bronchoscopy and distal placement of a conventional intubation tube (in case of a confirmed injury) should then be performed. Furthermore, in case of suspected pneumothorax, chest tube placement in the respective pleural space should be done. While smaller tears might allow conservative treatment [5], larger tears require prompt surgical reconstruction, either through cervicotomy or thoracotomy, depending on the exact location and extent of the injury.

References

1. Cools-Lartigue J, Aboalsaud A, Gill H, Ferri L. Evolution of percutaneous dilatational tracheostomy--a review of current techniques and their pitfalls. *World J Surg.* 2013;37(7):1633-46.
2. Higgins KM, Punthakee X. Meta-analysis comparison of open versus percutaneous tracheostomy. *Laryngoscope.* 2007;117(3):447-54.
3. Dempsey GA, Grant CA, Jones TM. Percutaneous tracheostomy: a 6 yr prospective evaluation of the single tapered dilator technique. *Br J Anaesth.* 2010;105(6):782-8.

4. Kearney PA, Griffen MM, Ochoa JB, Boulanger BR, Tseui BJ, Mentzer RM Jr. A single-center 8-year experience with percutaneous dilational tracheostomy. *Ann Surg.* 2000;231(5):701-9.
5. Cardillo G, Carbone L, Carleo F, Batzella S, Jacono RD, Lucantoni G, et al. Tracheal lacerations after endotracheal intubation: a proposed morphological classification to guide non-surgical treatment. *Eur J Cardiothorac Surg.* 2010;37(3):581-7.